

Diffuse Axonal Injury in Head Trauma

**Douglas H. Smith, MD; David F. Meaney, PhD;
William H. Shull, MD**

Background: Diffuse axonal injury (DAI) is one of the most common and important pathologic features of traumatic brain injury (TBI). The susceptibility of axons to mechanical injury appears to be due to both their viscoelastic properties and their high organization in white matter tracts. Although axons are supple under normal conditions, they become brittle when exposed to rapid deformations associated with brain trauma. Accordingly, rapid stretch of axons can damage the axonal cytoskeleton resulting in a loss of elasticity and impairment of axoplasmic transport. Subsequent swelling of the axon occurs in discrete bulb formations or in elongated varicosities that accumulate transported proteins. Calcium entry into damaged axons is thought to initiate further damage by the activation of proteases. Ultimately, swollen axons may become disconnected and contribute to additional neuropathologic changes in brain tissue. DAI may largely account for the clinical manifestations of brain trauma. However, DAI is extremely difficult to detect noninvasively and is poorly defined as clinical syndrome. **Conclusions:** Future advancements in the diagnosis and treatment of DAI will be dependent on our collective understanding of injury biomechanics, temporal axonal pathophysiology, and its role in patient outcome. **Key words:** amyloid- β , coma, diffuse axonal injury, diffuse brain injury, inertial brain injury, neurofilament, traumatic axonal injury

DIFFUSE AXONAL INJURY (DAI) is a “stealth” pathology of traumatic brain injury (TBI). Although found throughout the white matter, it comprises primarily microscopic damage, rendering it almost invisible to current imaging techniques. Yet, it is one of the most common and important pathologic features of TBI. It seems ironic that the size and organization of the human brain that allow us to design and drive automobiles are also our greatest liability of producing DAI in the event of a crash. Under the physical

forces such as shear that are commonly induce TBI, the human brain can literally pull itself apart. In particular, axons in the white matter appear poorly prepared to withstand damage from rapid mechanical deformation of the brain during trauma. Here, we will explore the current understanding of the causes and pathologic changes associated with DAI. In addition, we will examine deficiencies in our current ability to diagnose, grade, and treat DAI.

GENERAL CLASSIFICATION OF TBI

With more than 2 million patients affected in the United States each year, TBI is represented by a wide range of injury mechanisms and pathologies. As a simplification, two general categories of brain trauma have emerged, defined as “focal” and “diffuse” brain injury. Notably, however, these two forms of injury are commonly found together. Focal brain injury is typically associated with blows to the head that may produce cerebral contusions

From the Departments of Neurosurgery (Dr. Smith), Bioengineering (Dr. Meaney), and Rehabilitation Medicine (Dr. Shull), University of Pennsylvania, Philadelphia, Pennsylvania.

This work was funded, in part, by NIH grants AG 12527, NS38104, NS08803 (Smith), NS35712, and CDC R49/CCR312712 (Meaney).

Corresponding author: Douglas H. Smith, MD, Department of Neurosurgery, University of Pennsylvania, 3320 Smith Walk, 105 Hayden Hall, Philadelphia, PA 19104 (e-mail: smithdou@mail.med.upenn.edu).

and hematomas.¹⁻³ Diffuse brain injury may occur in the absence of impact forces, but is dependent on inertial forces that are commonly produced by motor vehicle crashes and, in some cases, falls and assaults.⁴⁻⁸ These inertial forces are a result of rapid head rotational motions, which deform the white matter and lead to DAI, commonly referred to as “shearing” brain injury (Figure 1). Although coined as “diffuse,” the pattern of axonal damage in the white matter is more accurately described as multifocal, appearing throughout the deep and subcortical white matter and is particularly common in midline structures including the splenium of the corpus callosum and brainstem. In mild to low moderate DAI, there is often a remarkable absence of macroscopic pathology and the brains may appear normal upon radiologic examination.⁹⁻¹¹ Nonetheless, microscopic examination of the brain tissue reveals the pathologic signature of DAI: a multitude of swollen and disconnected axons¹² (Figure 2). In DAI at high severity, axonal pathology is accompanied by tissue tears in the white matter and intraparenchymal hemorrhage.^{2,13}

BIOMECHANICS OF DAI

The principal mechanical force associated with the induction of DAI is rotational acceleration of the brain resulting from unrestricted head movement in the instant after

injury.^{7,14-18} This inertial loading to the brain induces dynamic shear, tensile, and compressive strains within the tissue leading to dynamic tissue deformation. For the development of DAI, the size of the human brain plays an important role because of the substantial mass effects during injury that result in high strains between regions of tissue.¹⁹ Under normal daily activities brain tissue is compliant and ductile to stretch and easily recovers its original geometry. In contrast, under severe circumstances, when the strain is rapidly applied, such as during an automobile crash, the brain tissue acts far stiffer, essentially becoming more brittle. Thus rapid uniaxial stretch or “tensile elongation” of axons is thought to result in damage of the axonal cytoskeleton.²⁰⁻²² This classic viscoelastic response to rapid deformation prompts a classification of *dynamic* injuries, in which the applied forces occur in less than 50 milliseconds.²³ Accordingly, axonal injury is dependent on both the magnitude of strain and rate of strain during brain trauma.

Evolution of axonal pathology after brain trauma

Disconnection of axons at the time of brain trauma (primary axotomy) is a relatively rare occurrence, with the exception of tissue tearing in the white matter in severe brain injury. Rather, axonal pathology has been shown to develop over the

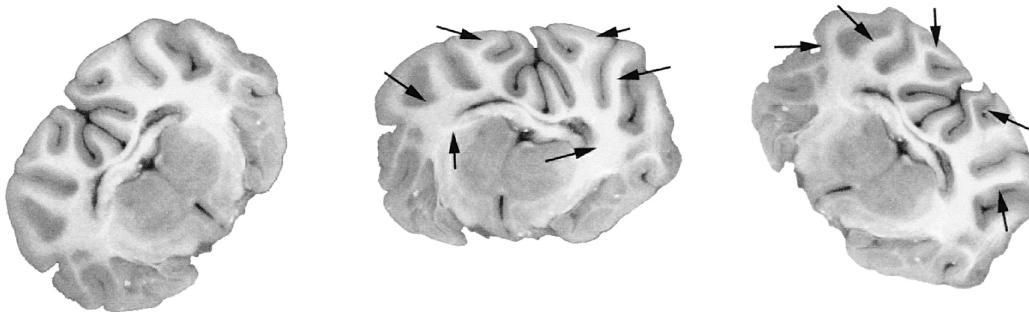


Fig 1. Rapid rotational acceleration/deceleration of the head of a pig in the coronal plane. On the left, the brain is at rest; in the middle, the brain is rapidly accelerated; on the right, the brain is rapidly decelerated. This inertial loading to the brain induces dynamic shear, tensile, and compressive strains within the white matter leading to dynamic tissue deformation (arrows), and ultimately, diffuse axonal injury.

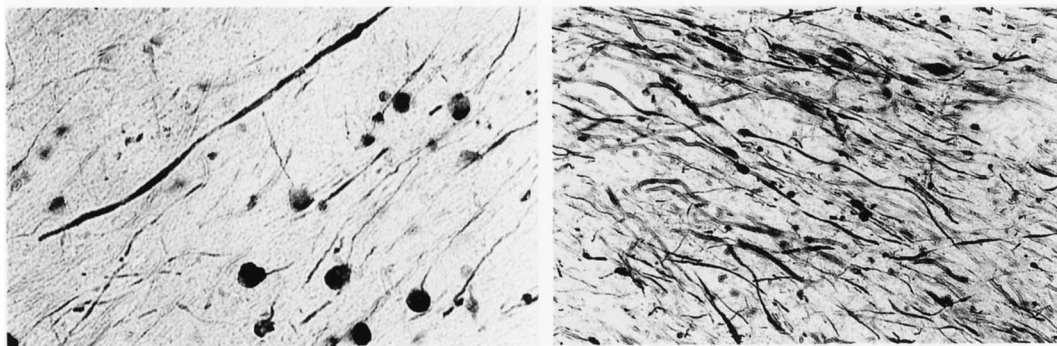


Fig 2. Photomicrographs demonstrating traumatic axonal pathology revealed by immunoreactivity of accumulating neurofilament protein. Darkly stained profiles show axonal pathology in the subcortical white matter (left) and brainstem (right), represented by elongated varicose swellings and axonal bulbs that form at the terminal stump of disconnected axons.

course of hours to days after injury and has even been observed months later.²⁴⁻²⁷ Within seconds of dynamic axonal stretch *in vitro*, axons can become temporarily undulated and misaligned from some loss of elasticity resulting from cytoskeletal damage.²⁸ Although axons may slowly recover back to their prestretch orientation and shape, there is a characteristic evolution of physical and physiologic changes. In particular, mechanical damage to sodium channels may result in massive influx of sodium with resultant swelling.²⁰ This sodium influx also triggers massive calcium entry through voltage-sensitive calcium channels and reversal of sodium/calcium exchangers.^{20,29} In turn, the increased intracellular calcium may play a role in the activation of proteolytic activity, as has been extensively examined.³⁰⁻³⁴ Adding to the immediate mechanical damage to the axonal cytoskeleton, further delayed damage may occur because of calcium-mediated proteolysis. This acute and delayed cytoskeletal damage is thought to result in impaired transport and accumulation of axonal transport proteins within axonal swellings.^{12,31-33,35-38} These swellings are characterized as two general forms; elongated varicosities or discrete bulb formations (see Figure 2). The most commonly used markers of protein accumulations in axonal swellings are the fast

transport β -amyloid precursor protein (APP) and the slow transport neurofilament (NF) proteins.^{8,39-43}

Thereafter, from days to months the course of evolving axonal pathology includes progressive disorganization of the axonal cytoskeleton and progressive protein accumulations, leading to disconnection of axon (secondary axotomy) with the signature pathologic feature of a bulb formation at the terminal end of the axon (previously referred to as “terminal clubbing” and “retraction balls”). It is important to consider that axonal disconnection in the white matter represents a final event in which the parent neuron has permanently lost the ability to communicate with its target at the other end of the tract. Although some DAI patients can achieve functional recovery, actual repair is limited to localized plasticity in the gray matter and potential mending of damaged axons in the white matter that did not disconnect.

Coma and DAI

Coma is the most common immediate impairment that has been associated with the severity of DAI. Indeed, an important difference between focal and diffuse brain injury is the source and character of post-traumatic coma resulting from these two

general forms of injury. Focal brain injury may include mass effects from hemorrhagic contusion or hematoma, which can induce herniation and brainstem compression.¹ Resultant coma may not be immediate, but develop in a secondary fashion. Much in contrast to these mechanisms of producing coma, in a landmark study, Gennarelli and colleagues demonstrated that DAI can be a sole source for posttraumatic coma. Specifically, they observed that nonimpact rotational acceleration applied to the heads of nonhuman primates could induce an immediate and prolonged posttraumatic unconsciousness and DAI in the absence of mass lesions.⁷ Our laboratory has more recently found that coma is dependent on both the plane of head rotational acceleration and the resulting distribution of axonal pathology.⁴⁴ In particular, axonal injury in the brainstem appears to be a primary factor in the generation of coma with DAI. Therefore, the depth and duration of coma with DAI may not be ideal measures of the relative extent of axonal pathology in the cerebral hemispheres or to gauge potential recovery of the patient.

DAI and a potential link with Alzheimer's disease

Mounting evidence suggests that brain trauma may have prolonged effects and initiate insidiously progressive neurodegenerative processes. Previously, postmortem histopathologic analysis of brains from boxers with *dementia pugilistica* ("punch-drunk syndrome") revealed neurofibrillary tangles and diffuse plaques composed of amyloid- β peptides ($A\beta$ s) similar to the hallmark lesions of Alzheimer disease (AD).^{45,46} Subsequently, a single incident of brain trauma was shown to induce the formation of $A\beta$ plaques within days after injury,^{47,48} and a large increase in $A\beta$ peptides has been found in the cerebrospinal fluid of brain-injured patients.⁴⁹

It has long been suspected that accumulated APP in damaged axons could provide ample substrate for $A\beta$ production.^{42,50,51} In-

deed, immunohistochemical detection of APP accumulation in axons throughout the white matter has become a standard method to identify DAI in human brains.^{40,42,52,53} However, extensive axonal $A\beta$ accumulation has only recently been identified in DAI in humans and animals models of brain trauma.^{27,54-56} These axonal $A\beta$ accumulations are often found in proximity to $A\beta$ plaques in both the white and gray matter. Overall, these observations suggest that damaged axons serve as a key source of $A\beta$, which can be released into the surrounding tissue from lysis or leakage of axonal bulbs. However, the clinical implications of this pathologic process have yet to be fully elucidated.

DIAGNOSIS OF DAI

After fatal brain trauma, DAI can be readily detected using immunohistochemical methods on brain sections. However, in survivors, DAI is virtually invisible to conventional brain imaging techniques, and is only hinted at if it is accompanied by macroscopic changes, such as white matter tears and parenchymal hemorrhage found in severe cases. The predominant pathology of DAI—microscopic axonal swellings—has proven extremely difficult to illuminate with noninvasive methods despite its extensive nature. Accordingly, patients and animal models with little macroscopic injury after diffuse brain injury typically have normal appearing images of the brain.^{11,57,58} This has led many to believe that axonal pathology is substantially underdiagnosed. Clinically, DAI is often a "diagnosis of exclusion" based on the inability of conventional imaging techniques to detect brain pathology despite overt symptoms, such as prolonged unconsciousness or cognitive dysfunction after brain trauma (Figure 3). Because of this diagnostic deficiency, the relative role of DAI in mild-to-moderate brain injury remains unclear.

Nonetheless, several new imaging and spectroscopic techniques are being developed that appear to better illuminate brain regions with axonal pathology. These include

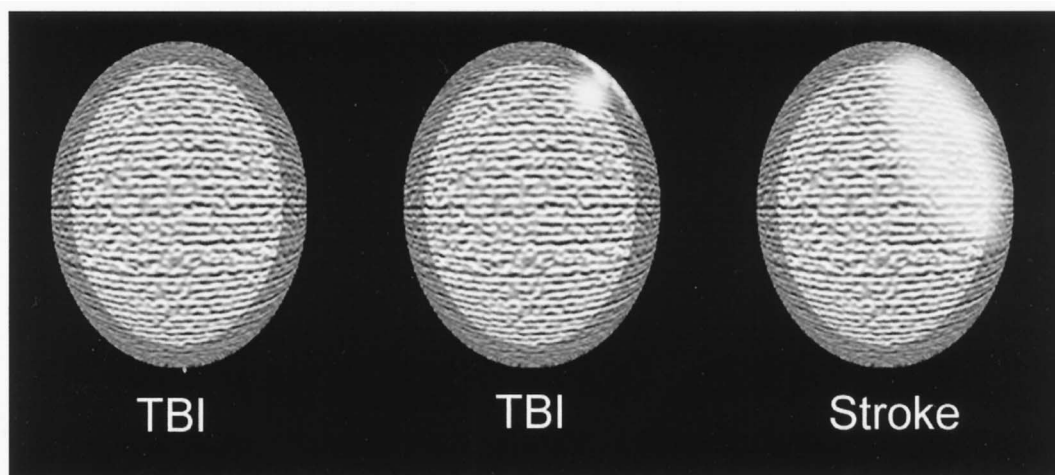


Fig 3. Three idealized brain images of hypothetical cases used to illustrate the poor prognostic value of current imaging techniques for traumatic brain injury (gray region represents gray matter, white region represents white matter). No changes are found in the image on the left and only focal changes (hyperintensities) are found on the image in the middle (subdural hematoma and small contusion) after brain trauma in two young adults. However, it is not uncommon to find that such patients have persisting impairments such as loss of attention, memory, and executive function. As a diagnosis of exclusion, the predominant pathology responsible for these deficits is diffuse axonal injury (DAI), which was invisible on the images. Contrast these circumstances with stroke. Often, ischemic damage resulting from stroke can occupy large regions of the brain and is readily visible using current imaging techniques, as represented by the hyperintense area in the image on the right. Nonetheless, even though these patients are typically elderly, their symptoms often resolve. Collectively, these hypothetical cases teach us that, although DAI is microscopic and not easy to detect, its diffuse nature may have far greater clinical implications than overt focal damage.

the magnetic resonance imaging (MRI) techniques of diffusion weighted imaging and magnetization transfer imaging, both of which take advantage of the molecular disarrangement of the white matter tracts with diffuse axonal pathology. In addition, magnetic resonance spectroscopy techniques used on standard MRI machines have also shown promise in revealing DAI.⁵⁸⁻⁶⁵ In the anticipation that therapies for DAI will be developed, it remains imperative that sensitive noninvasive techniques are fully developed for diagnosis.

TREATMENT OF DAI

Although an arsenal of agents has been shown to be therapeutic in rodent brain impact models,⁵³ none have been translated

into clinical efficacy. Sadly, all phase III clinical trials evaluating treatments for human brain trauma have failed miserably. Reasons for this are certainly multifactorial, but we must take into account that few of these therapies specifically targeted one of the most important pathologic features of human brain injury: DAI. An exception is the use of cerebral hypothermia, which was shown to reduce the number of axonal injury profiles and improve behavioral outcome in animal models of brain trauma.⁶⁶⁻⁶⁹ Unfortunately, a recent multicenter clinical trial evaluating hypothermia in severely brain-injured patients also failed to demonstrate efficacy. Alternative methods such as inhibiting calcium-mediated proteolysis or modulating mitochondrial permeability have recently shown promise in preserving axons in animal models of brain

trauma.^{37,67,70-75} Overall, advancement in our understanding of the temporal progression and pathophysiology of traumatic axonal injury is essential for the development of therapies aimed at repairing injured axons and preventing further damage.

TBI GRADING AND OUTCOME: THE POTENTIAL ROLE OF DAI

Although behavioral manifestations of damage in discrete brain regions after TBI have been extensively examined and characterized, the functional diagnosis of DAI has yet to be developed. To begin this endeavor, we must evaluate the clinical spectrum of TBI. TBI is typically classified according to clinical criteria, specifically the lowest Glasgow Coma Scale (GCS) score in the first 48 hours (severe TBI = 3-8, moderate TBI = 9-12, mild TBI = 13-15).⁷⁶ Mild TBI includes patients sustaining blunt-based trauma or inertial injury, whereas the GCS is scored as 15 if loss of consciousness (<20-30 minutes), posttraumatic amnesia (<24 hours), transient confusion, or any alteration in mental status was present.⁷⁷ Most clinicians will upgrade a patient to moderate TBI if there are any positive findings of neuroimaging based on outcome studies by Williams and Levin.⁷⁸ Thus, by default, focal neuroimaging findings such as contusions, hemorrhages, or hematomas occur only in moderate or severe TBI. However, the stratification of patients resting on the observation of overt neuroimaging changes ignores the extent of DAI, which may have the greatest implications in the outcome of the patient (see Figure 3). It is well-recognized that mild brain injury patients often have persisting difficulties with concentration and memory. By exclusion, it is thought that these deficits reflect DAI. It stands to reason, therefore, that the severity of DAI might correlate with certain clinical impairments and prognoses of functional recovery in mild as well as moderate and severe TBI. Despite the inherent heterogeneity of TBI, we must attempt to discern

these key characteristics that may ultimately define a "DAI syndrome."

The clinical manifestations of mild TBI may offer the best clues to a potential DAI syndrome because there is little or no macroscopic damage that might cloud interpretation. These changes include physical impairments, cognitive impairments, mood disturbances, and behavioral impairments. Physical impairments include an assortment of daytime fatigue, disequilibrium, phonophobia, tinnitus, photophobia, blurry vision, nausea, and headaches. It should be noted, however, that headaches are not likely due to injury in the brain, but rather from cervical or cranial injury.⁷⁹ Cognitive impairments encompass problems with attention, memory, and executive functions (eg, speed of processing, reasoning and mental flexibility). Mood disturbances and behavioral impairments are most commonly demonstrated by insomnia and behavioral dyscontrol (eg, irritability, easily triggered anger), but also as depressed mood and anxiety. Although general cortical function is intact, any combination of these "mild" symptoms can be devastating for the patients and their families.

The clinical manifestations of severe TBI are far more overt and are more likely to include brainstem structures and pathways. Initially, the extent and character of the injury is often masked by impaired consciousness and arousal. As consciousness improves, multiple severe impairments are typically observed in these patients. Cranial nerve dysfunction including ophthalmoparesis, olfactory, and gustatory problems, dysphagia, and vestibulopathy are common symptoms. Motor impairments range from tetraparesis to hemiparesis indicating that perhaps the distribution and extent of axonal pathology in DAI can vary unilaterally. Involuntary movements, spasticity, tremors, and dyspraxia can occur alone or in combinations. Perhaps the most common and important impairment in severe TBI patients is cognitive dysfunction. Although virtually all aspects of cognition are affected, the most challenging to

restore are impairments in memory and orientation, suggesting a selective vulnerability of pathways affecting these functions. Axonal pathology in frontolimbic pathways may be a key mechanism leading to agitation, inappropriate behavior, and extreme behavioral dyscontrol. Damage to other subcortical structures such as the hypothalamus and pituitary gland commonly results in a wide variety of metabolic and neuroendocrine disorders. Although there is extensive evidence that DAI plays an important role in these impairments, in most cases of severe

TBI, it is difficult to determine the relative contribution of axonal pathology resulting from mechanical injury versus superimposed hypoxia or mass effect from hematomas or cerebral edema.

As with the need to improve noninvasive imaging techniques, advancement in our ability to diagnose DAI based on mental and physical assessment is imperative to properly determine prognosis and also in the anticipation that therapies will be developed to specifically target the short- and long-term consequences of DAI.

REFERENCES

1. Adams JH, Graham DI, Gennarelli TA. Head injury in man and experimental animals: neuropathology. *Acta Neurochir Suppl (Wien)*. 1983;32:15-30.
2. Gennarelli TA. Mechanisms of brain injury. *J Emerg Med*. 1993;11(Suppl 1):5-11.
3. Graham DI, McLellan D, Adams JH, Doyle D, Kerr A, Murray LS. The neuropathology of the vegetative state and severe disability after non-missile head injury. *Acta Neurochir Suppl (Wien)*. 1983;32:65-67.
4. Adams JH, Doyle D, Ford I, Gennarelli TA, Graham DI, McLellan DR. Diffuse axonal injury in head injury: definition, diagnosis and grading. *Histopathology*. 1989;15:49-59.
5. Adams JH, Doyle D, Graham DI, Lawrence AE, McLellan DR. Diffuse axonal injury in head injuries caused by a fall. *Lancet*. 1984;2:1420-1422.
6. Blumberg PC, Jones NR, North JB. Diffuse axonal injury in head trauma. *J Neurol Neurosurg Psychiatry*. 1989;52:838-841.
7. Gennarelli TA, Thibault LE, Adams JH, Graham DI, Thompson CJ, Marcincin RP. Diffuse axonal injury and traumatic coma in the primate. *Ann Neurol*. 1982;12:564-574.
8. Grady MS, McLaughlin MR, Christman CW, Valadka AB, Fligner CL, Povlishock JT. The use of antibodies targeted against the neurofilament subunits for the detection of diffuse axonal injury in humans. *J Neuropathol Exp Neurol*. 1993;52:143-152.
9. Blumberg PC, Scott G, Manavis J, Wainwright H, Simpson DA, McLean AJ. Staining of amyloid precursor protein to study axonal damage in mild head injury. *Lancet*. 1994;344:1055-1056.
10. Jane JA, Steward O, Gennarelli T. Axonal degeneration induced by experimental noninvasive minor head injury. *J Neurosurg*. 1985;62:96-100.
11. Mittl RL, Grossman RI, Hiehle JF, et al. Prevalence of MR evidence of diffuse axonal injury in patients with mild head injury and normal head CT findings. *AJNR Am J Neuroradiol*. 1994;15:1583-1589.
12. Povlishock JT. Traumatically induced axonal injury: pathogenesis and pathobiological implications. *Brain Pathol*. 1992;2:1-12.
13. Ommaya AK, Gennarelli TA. Cerebral concussion and traumatic unconsciousness. Correlation of experimental and clinical observations of blunt head injuries. *Brain*. 1974;97:633-654.
14. Gennarelli TA. Mechanisms of brain injury. *J Emerg Med*. 1993;11(Suppl 1):5-11.
15. Meaney DF, Smith DH, Shreiber DI, et al. Biomechanical analysis of experimental diffuse axonal injury. *J Neurotrauma*. 1995;12:689-694.
16. Ommaya AK, Hirsch AE. Tolerances for cerebral concussion from head impact and whiplash in primates. *J Biomech*. 1971;4:13-21.
17. Smith DH, Chen XH, Xu BN, McIntosh TK, Gennarelli TA, Meaney DF. Characterization of diffuse axonal pathology and selective hippocampal damage following inertial brain trauma in the pig. *J Neuropathol Exp Neurol*. 1997;56:822-834.
18. Lusardi TA, Smith DH, Wolf JA, Meaney DF. The separate roles of calcium and mechanical forces in mediating cell death in mechanically injured neurons. *Biorheology*. 2002;40:401-409.
19. Meaney DF, Smith DH, Shreiber DI, et al. Biomechanical analysis of experimental diffuse axonal injury. *J Neurotrauma*. 1995;12:689-694.
20. Wolf JA, Stys PK, Lusardi T, Meaney D, Smith DH. Traumatic axonal injury induces calcium influx modulated by tetrodotoxin-sensitive sodium channels. *J Neurosci*. 2001;21:1923-1930.
21. Smith DH, Wolf JA, Lusardi TA, Lee VM, Meaney DF.

- High tolerance and delayed elastic response of cultured axons to dynamic stretch injury. *J Neurosci*. 1999;19:4263-4269.
22. Gennarelli TA, Thibault LE, Tipperman R, et al. Axonal injury in the optic nerve: a model simulating diffuse axonal injury in the brain. *J Neurosurg*. 1989;71:244-253.
 23. Metz H, McElhane J, Ommaya AK. A comparison of the elasticity of live, dead, and fixed brain tissue. *J Biomech*. 1970;3:453-458.
 24. Adams JH, Graham DI, Murray LS, Scott G. Diffuse axonal injury due to nonmissile head injury in humans: an analysis of 45 cases. *Ann Neurol*. 1982;12:557-563.
 25. Christman CW, Grady MS, Walker SA, Holloway KL, Povlishock JT. Ultrastructural studies of diffuse axonal injury in humans. *J Neurotrauma*. 1994;11:173-186.
 26. Pierce JE, Smith DH, Trojanowski JQ, McIntosh TK. Enduring cognitive, neurobehavioral and histopathological changes persist for up to one year following severe experimental brain injury in rats. *Neuroscience*. 1998;87:359-369.
 27. Iwata A, Chen XH, McIntosh TK, Browne KD, Smith D. Long-term accumulation of amyloid-beta in axons following brain trauma without persistent upregulation of amyloid precursor protein genes. *J Neuropathol Exp Neurol*. 2002;61:1056-1068.
 28. Smith DH, Wolf JA, Lusardi TA, Lee VM, Meaney DF. High tolerance and delayed elastic response of cultured axons to dynamic stretch injury. *J Neurosci*. 1999;19:4263-4269.
 29. Stys PK, Waxman SG, Ransom BR. Na(+)-Ca2+ exchanger mediates Ca2+ influx during anoxia in mammalian central nervous system white matter. *Ann Neurol*. 1991;30:375-380.
 30. Buki A, Siman R, Trojanowski JQ, Povlishock JT. The role of calpain-mediated spectrin proteolysis in traumatically induced axonal injury. *J Neuropathol Exp Neurol*. 1999;58:365-375.
 31. McCracken E, Hunter AJ, Patel S, Graham DI, Dewar D. Calpain activation and cytoskeletal protein breakdown in the corpus callosum of head-injured patients. *J Neurotrauma*. 1999;16:749-761.
 32. Pike BR, Zhao X, Newcomb JK, Posmantur RM, Wang KK, Hayes RL. Regional calpain and caspase-3 proteolysis of alpha-spectrin after traumatic brain injury. *Neuroreport*. 1998;9:2437-2442.
 33. Posmantur R, Hayes RL, Dixon CE, Taft WC. Neurofilament 68 and neurofilament 200 protein levels decrease after traumatic brain injury. *J Neurotrauma*. 1994;11:533-545.
 34. Saatman KE, Bozyczko-Coyne D, Marcy V, Siman R, McIntosh TK. Prolonged calpain-mediated spectrin breakdown occurs regionally following experimental brain injury in the rat. *J Neuropathol Exp Neurol*. 1996;55:850-860.
 35. Hall GF, Lee VM. Neurofilament sidearm proteolysis is a prominent early effect of axotomy in lamprey giant central neurons. *J Comp Neurol*. 1995;353:38-49.
 36. Maxwell WL, Kosanlavit R, McCreath BJ, Reid O, Graham DI. Freeze-fracture and cytochemical evidence for structural and functional alteration in the axolemma and myelin sheath of adult guinea pig optic nerve fibers after stretch injury. *J Neurotrauma*. 1999;16:273-284.
 37. Posmantur R, Kampfl A, Siman R, et al. A calpain inhibitor attenuates cortical cytoskeletal protein loss after experimental traumatic brain injury in the rat. *Neuroscience*. 1997;77:875-888.
 38. Povlishock JT, Marmarou A, McIntosh T, Trojanowski JQ, Moroi J. Impact acceleration injury in the rat: evidence for focal axolemmal change and related neurofilament sidearm alteration. *J Neuropathol Exp Neurol*. 1997;56:347-359.
 39. Blumberg PC, Scott G, Manavis J, Wainwright H, Simpson DA, McLean AJ. Topography of axonal injury as defined by amyloid precursor protein and the sector scoring method in mild and severe closed head injury. *J Neurotrauma*. 1995;12:565-572.
 40. Gentleman SM, Nash MJ, Sweeting CJ, Graham DI, Roberts GW. Beta-amyloid precursor protein (beta APP) as a marker for axonal injury after head injury. *Neurosci Lett*. 1993;160:139-144.
 41. Pierce JE, Trojanowski JQ, Graham DI, Smith DH, McIntosh TK. Immunohistochemical characterization of alterations in the distribution of amyloid precursor proteins and beta-amyloid peptide after experimental brain injury in the rat. *J Neurosci*. 1996;16:1083-1090.
 42. Sherriff FE, Bridges LR, Sivaloganathan S. Early detection of axonal injury after human head trauma using immunocytochemistry for beta-amyloid precursor protein. *Acta Neuropathol (Berl)*. 1994;87:55-62.
 43. Yaghmai A, Povlishock J. Traumatically induced reactive change as visualized through the use of monoclonal antibodies targeted to neurofilament subunits. *J Neuropathol Exp Neurol*. 1992;51:158-176.
 44. Smith DH, Nonaka M, Miller R, et al. Immediate coma following inertial brain injury dependent on axonal damage in the brainstem. *J Neurosurg*. 2000;93:315-322.
 45. Roberts GW, Allsop D, Bruton C. The occult aftermath of boxing. *J Neurol Neurosurg Psychiatry*. 1990;53:373-378.
 46. Tokuda T, Ikeda S, Yanagisawa N, Ihara Y, Glenner GG. Re-examination of ex-boxers' brains using immunohistochemistry with antibodies to amyloid beta-protein and tau protein. *Acta Neuropathol (Berl)*. 1991;82:280-285.
 47. Graham DI, Gentleman SM, Lynch A, Roberts GW. Distribution of beta-amyloid protein in the brain following severe head injury. *Neuropathol Appl Neurobiol*. 1995;21:27-34.

48. Roberts GW, Gentleman SM, Lynch A, Graham DI. beta A4 amyloid protein deposition in brain after head trauma. *Lancet*. 1991;338:1422-1423.
49. Raby CA, Morganti-Kossmann MC, Kossmann T, et al. Traumatic brain injury increases beta-amyloid peptide 1-42 in cerebrospinal fluid. *J Neurochem*. 1998;71:2505-2509.
50. Bramlett HM, Kraydieh S, Green EJ, Dietrich WD. Temporal and regional patterns of axonal damage following traumatic brain injury: a beta-amyloid precursor protein immunocytochemical study in rats. *J Neuropathol Exp Neurol*. 1997;56:1132-1141.
51. Lewen A, Li GL, Nilsson P, Olsson Y, Hillered L. Traumatic brain injury in rat produces changes of beta-amyloid precursor protein immunoreactivity. *Neuroreport*. 1995;6:357-360.
52. Lambri M, Djurovic V, Kibble M, Cairns N, Al-Sarraj S. Specificity and sensitivity of betaAPP in head injury. *Clin Neuropathol*. 2001;20:263-271.
53. Arnsten FT, Smith DH. Neuroprotective and rehabilitative strategies following brain injury. *Cognitive Neurorehabilitation*. Cambridge University Press; 1999:113-135.
54. Stone JR, Okonkwo DO, Singleton RH, Mutlu LK, Helm GA, Povlishock JT. Caspase-3-mediated cleavage of amyloid precursor protein and formation of amyloid beta peptide in traumatic axonal injury. *J Neurotrauma*. 2002;19:601-614.
55. Smith DH, Chen XH, Nonaka M, et al. Accumulation of amyloid beta and tau and the formation of neurofilament inclusions following diffuse brain injury in the pig. *J Neuropathol Exp Neurol*. 1999;58:982-992.
56. Smith DH, Chen X-H, Iwata A, Graham DI. Amyloid-beta in axons after traumatic brain injury in humans. *J Neurosurg*. 2003;98:1072-1077.
57. Cecil KM, Hills EC, Sandel ME, et al. Proton magnetic resonance spectroscopy for detection of axonal injury in the splenium of the corpus callosum of brain-injured patients. *J Neurosurg*. 1998;88:795-801.
58. Kimura H, Meaney DE, McGowan JC, et al. Magnetization transfer imaging of diffuse axonal injury following experimental brain injury in the pig: characterization by magnetization transfer ratio with histopathologic correlation. *J Comput Assist Tomogr*. 1996;20:540-546.
59. Alsop DC, Murai H, Detre JA, McIntosh TK, Smith DH. Detection of acute pathologic changes following experimental traumatic brain injury using diffusion-weighted magnetic resonance imaging. *J Neurotrauma*. 1996;13:515-521.
60. Barzo P, Marmarou A, Fatouros P, Hayasaki K, Corwin F. Contribution of vasogenic and cellular edema to traumatic brain swelling measured by diffusion-weighted imaging. *J Neurosurg*. 1997;87:900-907.
61. Cecil KM, Lenkinski RE, Meaney DE, McIntosh TK, Smith DH. High-field proton magnetic resonance spectroscopy of a swine model for axonal injury. *J Neurochem*. 1998;70:2038-2044.
62. Gentry LR, Godersky JC, Thompson BH. Traumatic brain stem injury: MR imaging. *Radiology*. 1989;171:177-187.
63. Hanstock CC, Faden AI, Bendall MR, Vink R. Diffusion-weighted imaging differentiates ischemic tissue from traumatized tissue. *Stroke*. 1994;25:843-848.
64. McGowan JC, McCormack TM, Grossman RI, et al. Diffuse axonal pathology detected with magnetization transfer imaging following brain injury in the pig. *Magn Reson Med*. 1999;41:727-733.
65. Smith DH, Cecil KM, Meaney DE, et al. Magnetic resonance spectroscopy of diffuse brain trauma in the pig. *J Neurotrauma*. 1998;15:665-674.
66. Bramlett HM, Green EJ, Dietrich WD, Busto R, Globus MY, Ginsberg MD. Posttraumatic brain hypothermia provides protection from sensorimotor and cognitive behavioral deficits. *J Neurotrauma*. 1995;12:289-298.
67. Buki A, Koizumi H, Povlishock JT. Moderate post-traumatic hypothermia decreases early calpain-mediated proteolysis and concomitant cytoskeletal compromise in traumatic axonal injury. *Exp Neurol*. 1999;159:319-328.
68. Koizumi H, Povlishock JT. Posttraumatic hypothermia in the treatment of axonal damage in an animal model of traumatic axonal injury. *J Neurosurg*. 1998;89:303-309.
69. Marion DW, White MJ. Treatment of experimental brain injury with moderate hypothermia and 21-aminosteroids. *J Neurotrauma*. 1996;13:139-147.
70. Kampfl A, Posmantur RM, Zhao X, Schmutzhard E, Clifton GL, Hayes RL. Mechanisms of calpain proteolysis following traumatic brain injury: implications for pathology and therapy: implications for pathology and therapy: a review and update. *J Neurotrauma*. 1997;14:121-134.
71. Okonkwo DO, Buki A, Siman R, Povlishock JT. Cyclosporin A limits calcium-induced axonal damage following traumatic brain injury. *Neuroreport*. 1999;10:353-358.
72. Okonkwo DO, Pettus EH, Moroi J, Povlishock JT. Alteration of the neurofilament sidearm and its relation to neurofilament compaction occurring with traumatic axonal injury. *Brain Res*. 1998;784:1-6.
73. Okonkwo DO, Povlishock JT. An intrathecal bolus of cyclosporin A before injury preserves mitochondrial integrity and attenuates axonal disruption in traumatic brain injury. *J Cereb Blood Flow Metab*. 1999;19:443-451.
74. Saatman KE, Murai H, Bartus RT, et al. Calpain inhibitor AK295 attenuates motor and cognitive deficits following experimental brain injury in the rat. *Proc Natl Acad Sci USA*. 1996;93:3428-3433.
75. Scheff SW, Sullivan PG. Cyclosporin A significantly ameliorates cortical damage following experimental traumatic brain injury in rodents. *J Neurotrauma*. 1999;16:783-792.

76. Cope ND. The rehabilitation of traumatic brain injury. In: Kottke and Lehman, eds. *Krusen's Handbook of Physical Medicine and Rehabilitation*. Philadelphia: W. B. Saunders; 1990:1217-1251.
77. Kay T, Harrington DE, Adams R, et al. Definition of mild traumatic brain injury. *J Head Trauma Rehabil*. 1993;8:86-87.
78. Williams DH, Levin HS, Eisenberg HM. Mild head injury classification. *Neurosurgery*. 1990;27:422.
79. Zasler ND. Post-traumatic headache: caveats and controversies. *J Head Trauma Rehabil*. 1999;14:1-8.